

Clinical Case Study

Speedboat Submucosal Dissection (SSD) Using Advanced Energy for a LST- mixed lesion in the rectum extending to the dentate line

Dr. Salmaan Jawaid

MD, Therapeutic Endoscopist-Advanced Tissue Resection,

Baylor College of Medicine/St Lukes Medical Center Assistant Professor of Medicine

Patient History

A 54-year-old female presented for her initial screening colonoscopy and was found to have a 35mm LST- mixed lesion in the rectum extending to the dentate line (**Figure 1**). The lesion demonstrated a central nodule and contained depressed areas within the periphery (**Figure 2**). Biopsies revealed tubular adenoma with high-grade dysplasia.

The referring physician initially referred the patient to the colorectal surgeons due to the proximity of the lesion to the dentate line and the potential for a high-grade lesion. After discussion with the patient and the colorectal surgeon, the patient was referred to us to consider endoscopic resection to avoid potential surgical complications and injury to the anal sphincter.

After evaluating the lesion, the decision was made to pursue endoscopic submucosal dissection over endoscopic mucosal resection to provide the best chance for en bloc and curative resection. When determining which dissection knife and energy system to use, the decision was made to use Advanced Bipolar energy, instead of monopolar energy, to limit the amount of electrocautery applied past the dentate line, as this area of the anus can be quite sensitive to any manipulation. Moreover, using the Speedboat Inject device would allow quicker dissection by limiting the need for repeated instrument changes.

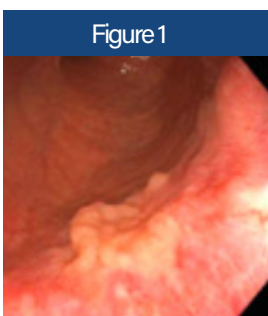


Figure 1

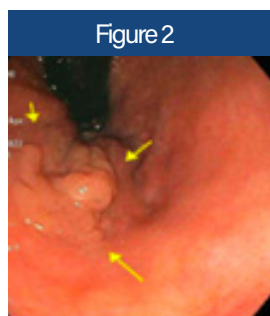


Figure 2

35mm rectal polyp extending to the dentate line, LST-mixed type. Central nodule with peripheral depressions were present concerning for a high-grade adenoma.

Procedure



A therapeutic flexible endoscope with a 3.8mm working channel was inserted into the rectum. The Speedboat Inject device was inserted through the working channel and the lesion edge was marked using the coagulation current. A distal (anal) mucosal incision at the dentate line was first created by using the injection needle of the Speedboat Inject device to create a submucosal bleb (using Hetastarch solution), followed by mucosal incision using cutting current (Figure 3). Submucosal dissection was then performed of the anal side of the lesion until about 1cm of the submucosa was dissected. A proximal (oral) mucosal incision was then created and

submucosal dissection was then performed in a similar manner. A tunnel was then created (Figure 4 and 5) using the Speedboat Inject device and both incisions were connected by performing submucosal dissection beginning at the anal aspect of the lesion extending to the oral side. Microwave coagulation of bleeding vessels was performed entirely using the Speedboat device, with no additional hemostatic devices needed. The gravity dependent lateral edge was then dissected followed by the anti-gravity lateral side finally to complete en bloc dissection (Figure 6).

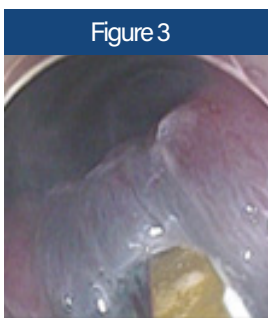


Figure 3
Mucosal incision beginning at the dentate line (anal side)




Figure 4
Creating submucosal tunnel

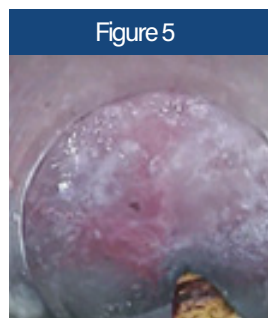


Figure 5

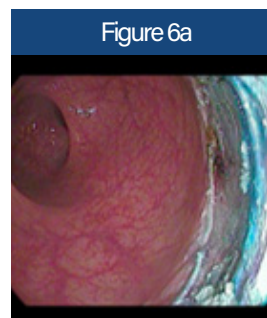

Figure 6a

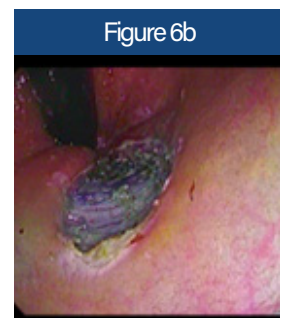

Figure 6b

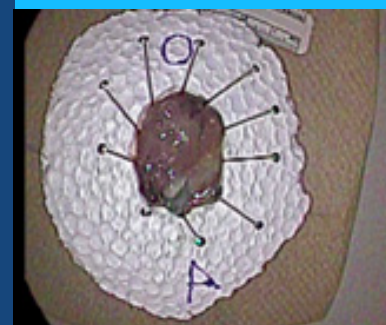Final resection bed with minimal thermal damage

Outcome

The entire procedure was completed in 65 minutes with no immediate complications. The patient was discharged home after the procedure as she had no pain around the rectum. Even 24 hours after the procedure, the patient reported no pain. Final pathology revealed tubular adenoma with high-grade dysplasia with clear vertical and lateral margins, demonstrating a curative dissection.

Conclusion

Use of the Speedboat Inject devices singlehandedly allowed safe and efficient curative resection of a large rectal lesion that extended to the dentate line. Its successful implementation prevented a major surgery, which carries inherent long-term complications. Application of Advanced Bipolar energy prevented excessive thermal damage at the dentate line, thereby minimizing post-procedural pain and allowing expedient discharge of the patient.



Final resected specimen